

# Helen M Morement

## CEO

### AMMF – The Cholangiocarcinoma Charity

07 December 2018

London



# AMMF

---

THE CHOLANGIOCARCINOMA CHARITY

A large, stylized logo featuring a dark blue liver shape with an orange bile duct structure. The text "CHOLANGIOCARCINOMA UK" is overlaid on the liver shape.

# CHOLANGIOCARCINOMA UK

## THE FACTS:

- Cholangiocarcinoma is the second most common primary liver cancer in the world
- In 2013 it caused 2,161 deaths in England alone\*

*\* Figures published June 2015 by the National Cancer Intelligence Network*


## THE FACTS:

- Cholangiocarcinoma is the second most common primary liver cancer in the world
- In 2013 it caused 2,161 deaths in England alone\*
- Fewer than 5% will survive one year from diagnosis
- The incidence is increasing, and we don't know why
- The age of those affected is getting lower, and we don't know why

*\* Figures published June 2015 by the National Cancer Intelligence Network*



Lucy-May



Sarah



Nicola



Greig



Andrew



Nick



Charlotte



Veronica

# THE MAJOR PROBLEMS

- It's difficult to diagnose clearly and accurately
- Most are diagnosed too late for potentially curative surgery
- The cause here in the West is generally unknown (it's sporadic)

# THE MAJOR PROBLEMS

- It's difficult to diagnose clearly and accurately
- Most are diagnosed too late for potentially curative surgery
- The cause here in the West is generally unknown (it's sporadic)
- **There's a lack of robust data ...**



# THE MAJOR PROBLEMS

There is a lack of robust data to prove what we are seeing.  
And...

*“Without data you’re just another person with an opinion.”*

W. Edwards Deming,  
Data Scientist (1900 – 1993)



# ICD-10

ICD-10 Version:2010

Search

bile duct cancer

[ Advanced Search ]

ICD-10

Versions - Languages

Info

ICD-10 Version:2010

I Certain infectious and parasitic diseases

II Neoplasms

C00-C97 Malignant neoplasms

C00-C75 Malignant neoplasms, stated or presumed to be primary, of specified sites, except of lymphoid, haematopoietic and related tissue

C00-C14 Malignant neoplasms of lip, oral cavity and pharynx

C15-C26 Malignant neoplasms of digestive organs

C15 Malignant neoplasm of oesophagus

C16 Malignant neoplasm of stomach

C17 Malignant neoplasm of small intestine

C18 Malignant neoplasm of colon

C19 Malignant neoplasm of rectosigmoid junction

C20 Malignant neoplasm of rectum

C21 Malignant neoplasm of anus and anal canal

C22 Malignant neoplasm of liver and intrahepatic bile ducts

C22.0 Malignant neoplasm: Liver cell carcinoma

C22.1 Malignant neoplasm: Intrahepatic bile duct carcinoma

C22.2 Malignant neoplasm: Hepatoblastoma

C22.3 Malignant neoplasm: Angiosarcoma of liver

C22.4 Malignant neoplasm: Other sarcomas of liver

C22.7 Malignant neoplasm: Other specified carcinomas of liver

C22.9 Malignant neoplasm: Liver, unspecified

C23 Malignant neoplasm of gallbladder

C24 Malignant neoplasm of other and unspecified parts of biliary tract

C22 Malignant neoplasm of liver and intrahepatic bile ducts

Excl.: biliary tract NOS (C24.9)

secondary malignant neoplasm of liver (C78.7)

C22.0 Liver cell carcinoma

Hepatocellular carcinoma

Hepatoma

C22.1 Intrahepatic bile duct carcinoma

Cholangiocarcinoma

C22.2 Hepatoblastoma

C22.3 Angiosarcoma of liver

Kupffer cell sarcoma

C22.4 Other sarcomas of liver

C22.7 Other specified carcinomas of liver

C22.9 Liver, unspecified

C23 Malignant neoplasm of gallbladder

C24 Malignant neoplasm of other and unspecified parts of biliary tract

Excl.: intrahepatic bile duct (C22.1)

C24.0 Extrahepatic bile duct

Biliary duct or passage NOS

Common bile duct

Cystic duct

Hepatic duct

C24.1 Ampulla of Vater


C24.8 Overlapping lesion of biliary tract


[See note 5 at the beginning of this chapter]

Malignant neoplasm involving both intrahepatic and extrahepatic bile ducts

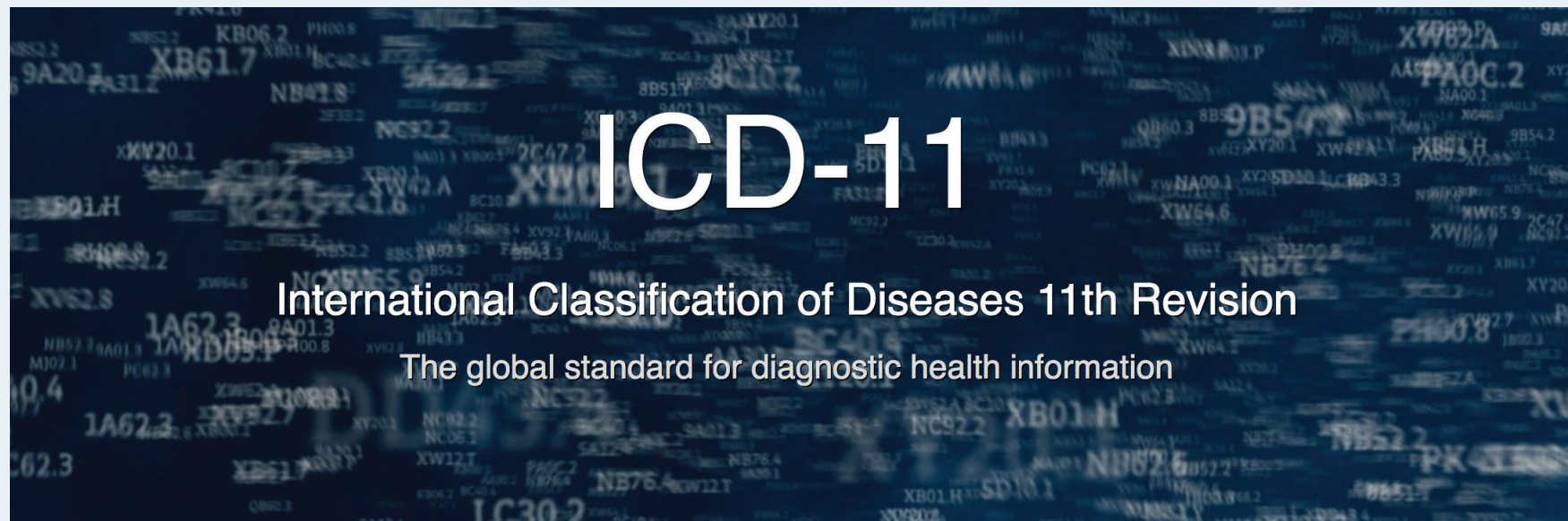
Malignant neoplasm of biliary tract whose point of origin cannot be classified to any one of the categories C22.0-C24.1

C24.9 Biliary tract, unspecified


**BASL**  
 British Association for the Study of the Liver

CHOLANGIOCARCINOMA  
 UK  


# INTERNATIONAL CLASSIFICATION OF DISEASES 11TH REVISION



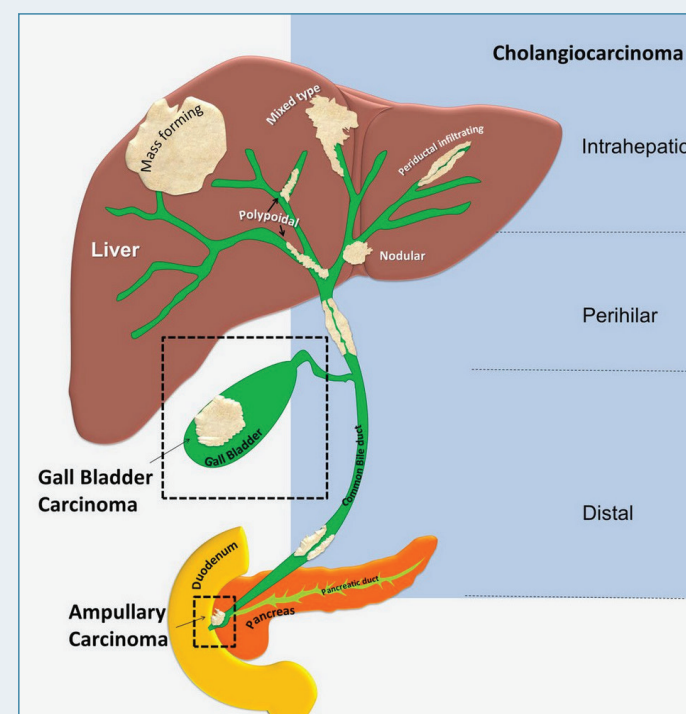
<https://icd.who.int>

# ICD-11 HAS RE-CODED CHOLANGIOCARCINOMA:

2C12.10 Intrahepatic cholangiocarcinoma

2C18.0 Hilar Cholangiocarcinoma

2C15.0 Extrahepatic cholangiocarcinoma:  
Adenocarcinoma of biliary tract,  
distal bile duct



A large, stylized logo featuring a dark blue liver shape with an orange bile duct structure. The text "CHOLANGIOCARCINOMA UK" is overlaid on the liver shape.

# CHOLANGIOCARCINOMA UK

# Thank you